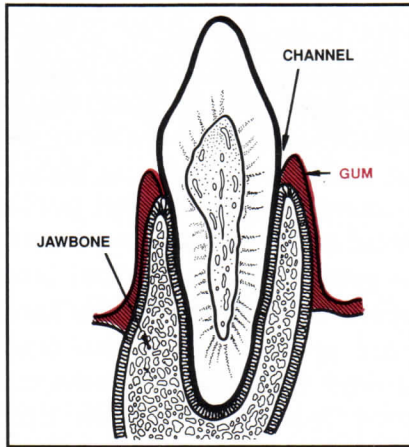
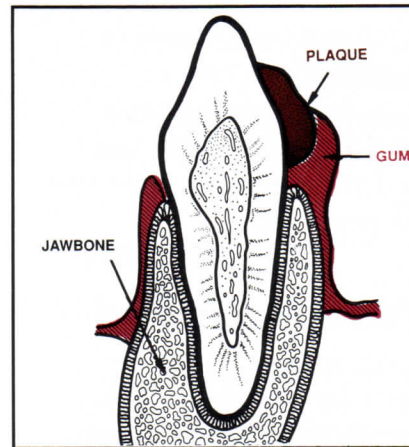


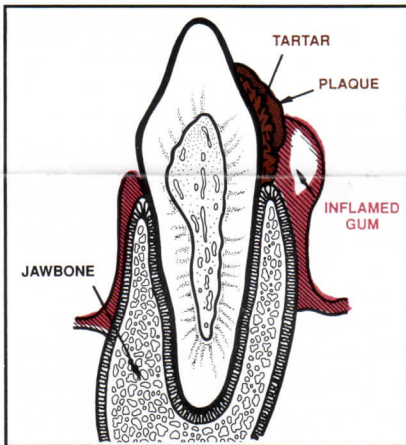
**A HEALTHY TOOTH AND THE FOUR STAGES OF PERIODONTAL DISEASE**



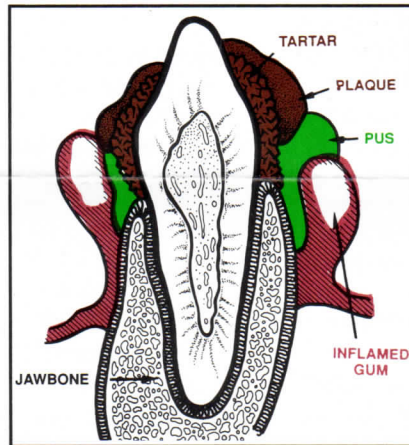
**FIGURE 1.** The healthy tooth. Note the channel formed between gum and tooth.



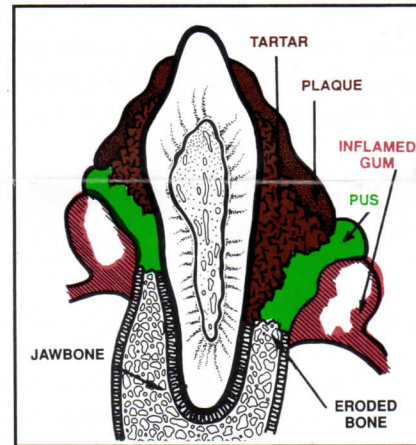
**FIGURE 2.** As food material accumulates in the groove, it adheres to the surface of the tooth and plaque is formed. (Stage 1)



**FIGURE 3.** Minerals seep into soft plaque and precipitate to form a hard, roughened tartar. (Stage 2)



**FIGURE 4.** Unattended, the plaque and tartar formations grow, pus builds up, and the gum is further separated from the tooth.



**FIGURE 5.** As toxic materials accumulate, the surrounding bone begins to erode.

*Illustrations courtesy of Nabisco*

**VETERINARY FILE: A HEALTHY TOOTH AND THE FOUR STAGES OF PERIODONTAL DISEASE**

**WHAT CAUSES PERIODONTAL DISEASE?**

Periodontal disease does not have any single cause. Instead, it usually is produced by some combination of potentially contributing factors.








Possible contributing factors are:

1. Soft or semi-moist diets.
2. Presence of dental plaque.
3. Advancing age.
4. Breed (certain breeds/heredity).
5. Oral injuries, including traumatic injuries (biting, rock chewing, etc.) and chemical injuries.
6. Abnormal dental occlusion.

In fact, almost anything that contributes to unclean teeth is a potential cause of periodontal disease.

**YOUR ORAL HEALTH CHECKLIST**

Here's a checklist to help you determine if your pet's mouth and gums are as healthy as they should be. If you find that you have checked any of these, you should make an appointment for your pet with your veterinarian.

-  Bad breath
-  Bleeding gums
-  Lumps or bumps in gums
-  Gingivitis (red, swollen gums)
-  Tartar (brown stains on teeth)
-  Ulcers or sores on gums
-  Loose, cracked, or broken teeth

**ANY FURTHER QUESTIONS YOU MAY HAVE CAN BE ANSWERED BY CALLING OUR OFFICE.  
PRACTICE OF VETERINARY MEDICINE, SURGERY AND DENTISTRY**